



Caseous Lymphadenitis Management in Goats

C. Kim Chapman, M.S., Small Ruminant Specialist, Utah State University Extension
Matthew J. Kennedy, M.S.P.H., Coordinator, East African Refugee Goat Project of Utah

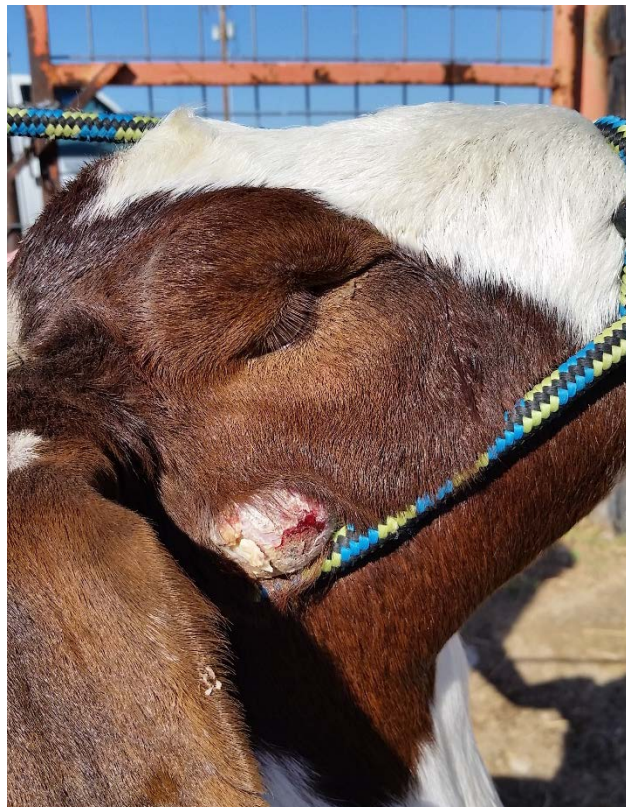
Introduction

Caseous Lymphadenitis (CL) is a chronically infectious, zoonotic disease of sheep and goats that is caused by the bacterium *Corynebacterium pseudotuberculosis*. CL causes abscesses in both goats and sheep which can be difficult to cure and can lead to reduced production and on occasion, death.

Found throughout the world, CL causes ulcerative lymphadenitis in horses and superficial abscesses in cattle, swine, rabbits, deer, laboratory animals, and humans.

Economic losses due to CL result from loss of breeding stock sales, reduced productivity, carcass condemnation due to internal abscesses, animal death, and abscesses that devalue hides.

C. pseudotuberculosis bacteria is hardy and can survive in the soil for up to 2 years, even in dry climates with high sun exposure. CL is transferred between animals or to humans through the skin or by ingestion, inhalation, or contact with contaminated equipment, facilities, pastures, and troughs. This transfer commonly occurs when an abscess ruptures and the contagious pus enters another animal through direct contact, open wounds, ingestion or via vectors such as flies. CL positive does can also transmit CL to kids through nursing if a CL abscess is found on the mammary gland. The disease can also be transferred through contaminated needles during vaccinations.



Clinical Signs

CL can occur both internally and externally in sheep and goats.

Figure 1: Abscess beginning to rupture naturally, abscesses that occur under the ear can be very hard to spot.

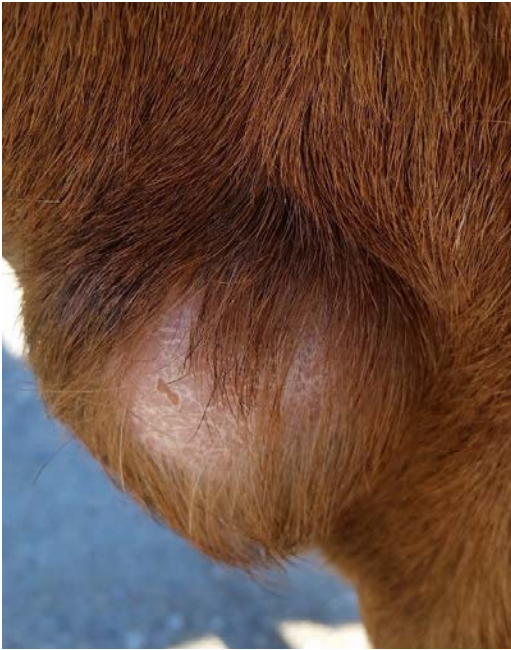

Figure 2: Abscess close to bursting under animals' left jaw near the neck. Note the loss of hair.

External Abscesses

Externally, CL often presents as abscesses visible behind the ears, beneath the jaw or neck, on the shoulders, in the rear flank region and occasionally behind the legs where the scrotum or udder




Figure 3: Abscess located on animals' neck. Some abscesses can be 3-4 inches across.

attaches. However, they can occur anywhere on the body. These abscesses are frequently, but not always, adjacent to lymph nodes. Most often abscesses present on the neck, jawline, and shoulder. The abscesses range from firm to soft when palpated. Some are well defined and rounded, and typically contain a pasty, thick white/ yellow/ greenish pus. The pus is generally odorless, but can have a strong odor in advanced abscesses.

Internal Abscesses

Internally, CL causes abscesses on the animals' organs and lymph nodes. Specific organs impacted may include the lungs, kidney and liver. These can only be seen during necropsy. Internal CL is often fatal to the animal, and generally causes chronic weight loss.

Typically, in goats, CL presents externally with more frequency than internally, while sheep are more prone to internal abscesses.

It can take 2 to 6 months for physical signs to present after infection.

Carcass Rejection

A carcass may be rejected (condemned) during processing if more than one abscess is found externally, or if there is the presence of internal abscesses. Animals with actively draining abscesses cannot be sold commercially.

General Herd CL Management

The following management suggestions can be implemented to reduce the likelihood of CL infection in a herd or to reduce it from spreading within a herd upon discovery.

- Constant vigilance.
 - Herd should be constantly monitored for presence of abscesses (cysts/boils/etc.).
 - Whenever animals are confined, such as during vaccinations or hoof trimming, thoroughly check each animal for clinical signs of the disease's presence.
 - Special care should be taken to check on the jawline, under the ears, the neck and behind the shoulders. See figures above.
- If a goat is found to have an abscess, **treat it as if it is CL!**

- Immediately isolate the goat from the rest of the herd, preferably in an area that can be easily disinfected.
- Wear gloves when draining the abscess to avoid infection.
- To take a sterile sample:
 - Scrub the area surrounding the abscess with chlorhexidine.
 - Remove residue with isopropyl alcohol.
 - With sterile syringe, collect sample from abscess.
 - Place the sample in a sterile vial and label it so it can be sent to a veterinary diagnostic lab for testing and identification.
- Use a disposable scalpel to cut the abscess and drain it, before it ruptures on its own.
 - Make the incision near the bottom of the abscess, to make draining easier.
- Create a cross cut (+) to better drain the abscess, as the fluid can be very thick.
- Completely drain the abscess. There is often a large amount of fluid present.
 - The abscess can be drained into a disposable plastic bag to make cleanup easier and reduce contamination of the isolation pen
- Flush the abscess cavity thoroughly with a diluted iodine solution.
 - Flush until no more pus can be seen coming from the drain.
 - Flush the wound daily for 3 days after treatment.
- Treat wound with scarlet oil or similar wound spray.
- Keep the infected animal isolated from the rest of the herd until the wound is completely healed
 - It is preferable to isolate the goats completely until the wound is scabbed over. They can then be allowed into the corral with the other treated goats until the wound is completely healed.
- Thoroughly disinfect the area where the isolated animals were housed using bleach or chlorhexidine. This disinfecting includes troughs, water buckets and structures.
- Rake up any bedding material, loose feed, or waste and burn it.
- Disinfect, incinerate or properly dispose of gloves, paper towels, scalpels, and lining material immediately after use.
- Keep thorough records of each animal with abscesses and results of diagnostic tests.
- Vaccinate the remainder of the herd to reduce the risk of new cases.
 - Develop an autogenous vaccine from collected samples within the herd
 - Test on a small number of goats first to assess potential side effects.
 - Purchase a commercially available goat specific CL vaccine to treat young, uninfected goats.
- Minimize the number of sharp surfaces in corral facilities to reduce disease spread.
 - Exposed nails, barbed wire, rough feeders, etc., may cause abscesses to rupture, spreading the disease to other animals in the herd.
- Improve/increase fly treatment to reduce disease spread.
- Disinfect hoof trimmers, shears, dehorers, etc., between individual animals.
- Consider culling older, infected does if it is possible.
- To reduce risk of introduction or spread, be cautious when introducing new animals into the herd.
 - Thoroughly inspect the animal for signs of current abscesses or scarring.
 - Infected bucks with open abscesses can quickly spread the disease to any doe they breed and should not be used for breeding purposes.

Implications for Disposal of CL Positive Animals

Scenario 1: Cull infected animals and sell them for meat.

- Animals with active infections cannot be sold until the abscess is completely healed.
- Animal must first be treated and completely healed before sale.
- Purchaser must be informed of the potential of CL being present internally in the carcass.
- Animal should be presented for harvest at a state inspected harvest facility or if the animal is being harvested on the farm, an individual trained to recognize internal CL abscesses should be present to reject the carcass if abscesses are found.
- Any animal sold that is found to have internal CL abscesses will be disposed of and the price refunded to the buyer so no part of the animal can be consumed.

Scenario 2: Treat breeding animals and reintroduce them to the herd.

- Follow the general herd CL management recommendations.
- Be even more vigilant in watching previously infected animals for recurrence.
 - Particular times to assess herd in order to reduce disease spread include prior to breeding and prior to kidding (abscesses on udders).
- Cull the animal when other production parameters warrant culling, or if there is a recurrence of the CL.

Conclusion

A CL diagnosis is not necessarily a death knell for an infected animal. However, management following a CL diagnosis must be increased to prevent the disease from spreading and becoming a persistent problem within the herd. CL can be managed to a successful conclusion if the proper management steps and vigilance are maintained.

Sources

- Leite-Browning, M.L., 2016. Caseous Lymphadenitis (CL) in Goats and Sheep, Alabama A&M University, <http://www.aces.edu/pubs/docs/U/UNP-0085/index2.tmpl> Accessed October 4, 2016.
- Pezzanite, L., Neary, M., Hutchens, T. and Scharko, P. 2009. *Common Diseases and Health Problems in Sheep and Goats*, Purdue University Extension Fact Sheet <https://www.extension.purdue.edu/extmedia/as/as-595-commondiseases.pdf> Accessed October 7, 2016.
- Washburn, K., 2014. *Caseous Lymphadenitis of Sheep and Goats*. The Merck Veterinary Manual, http://www.merckvetmanual.com/mvm/circulatory_system/lymphadenitis_and_lymphangitis/caseous_lymphadenitis_of_sheep_and_goats.html Accessed October 9, 2016.

Utah State University is committed to providing an environment free from harassment and other forms of illegal discrimination based on race, color, religion, sex, national origin, age (40 and older), disability, and veteran's status. USU's policy also prohibits discrimination on the basis of sexual orientation in employment and academic related practices and decisions. Utah State University employees and students cannot, because of race, color, religion, sex, national origin, age, disability, or veteran's status, refuse to hire; discharge; promote; demote; terminate; discriminate in compensation; or discriminate regarding terms, privileges, or conditions of employment, against any person otherwise qualified. Employees and students also cannot discriminate in the classroom, residence halls, or in on/off campus, USU-sponsored events and activities. This publication is issued in furtherance of Cooperative Extension work, acts of May 8 and June 30, 1914, in cooperation with the U.S. Department of Agriculture, Ken White, Vice President for Extension and Agriculture, Utah State University